

CASE REPORT

Endometrial polyp filled with gestational tissues remained undiscovered in an infertile woman for years: a case report

Najah Dhemesh^{1,*}, Maysam Hamsho¹ and Habib Jarbouh²¹Faculty of Medicine, University of Hama, Hama, Syria, ²Department of Pathology, Faculty of Medicine, Damascus University, Damascus, Syria

*Correspondence address. Faculty of Medicine, University of Hama, 0500 Hama, Syria. Tel: 00963933479486; E-mail: najah.dhemesh@gmail.com

Abstract

Recurrent pregnancy loss (RPL) is a common disease, which presents as two, three or more failed pregnancies. It is attributed to many risk factors, yet half of the cases are idiopathic. In this report, we present a case of a 44-year-old woman with a complaint of secondary infertility for 10 years and a history of three spontaneous abortions. Blood tests and images showed no abnormalities, except for hysteroscopy which showed a polyp-like mass. Pathology revealed an endometrial stroma showing severe decidualization with a lot of gestational villi showing fibrosis and hyaline degeneration, features of old gestational product death, with no glands crowding or cellular atypia. In this case, the conception products were not preceded with a miscarriage and did not cause any symptoms indicating its existing. The asymptomatic endometrial polyp filled with fibrotic gestational villi without a prior miscarriage is an unprecedented case in the medical literature.

INTRODUCTION

Recurrent pregnancy loss (RPL), or consecutive pregnancy loss, is a disease characterized by two, three or more failed pregnancies. It affects approximately 1–2% of reproductive women and is more common in women older than 40 years. RPL must be distinguished from sporadic pregnancy loss, or non-consecutive pregnancy loss, which occurs randomly in women's reproductive years in approximately 15% of pregnancies. While many cases are caused by several potential risk factors, including uterine anomalies, antiphospholipid syndrome, endocrinological abnormalities, and chromosomal abnormalities, up to 50% of RPL cases have no evident cause which requires further testing procedures to identify the underlying cause [1, 2].

Endometrial polyps (EP) are localized hyperplastic overgrowths of endometrium that contain both endometrial glands

and stroma. EP are one of the intrauterine abnormalities that may be seen during the infertility workup and are common among women with unexplained infertility [3].

CASE REPORT

A 44-year-old woman came to the clinic complaining of secondary infertility for about 10 years in which she had three gestations that were all ended with spontaneous abortions within about 1 month of gestation. The abortions were managed expectantly by her previous physician and stated as complete miscarriages depending on bleeding cease and ultrasound images. She had a normal regular menstrual cycle and her body mass index (BMI) was 21.8 with no other complaints or diseases and no medications. The patient had previously undergone a

Received: April 14, 2020; Revised: April 29, 2020; Accepted: May 3, 2020

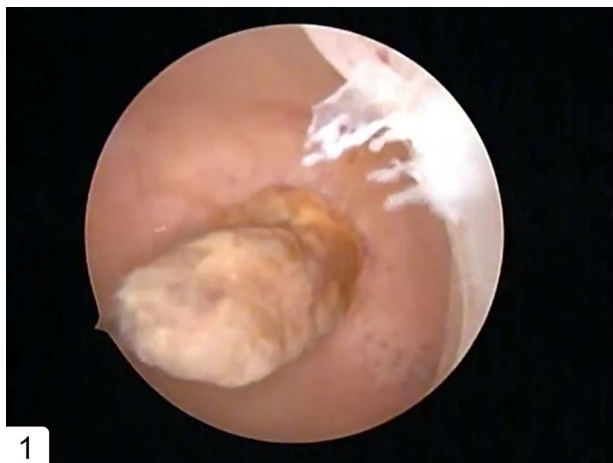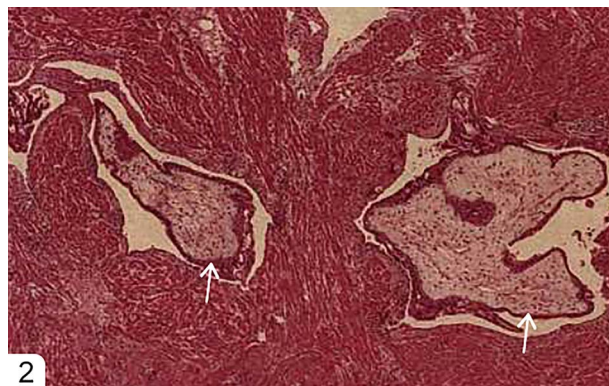
© The Author(s) 2020. Published by Oxford University Press.

This is an Open Access article distributed under the terms of the Creative Commons Attribution Non-Commercial License (<http://creativecommons.org/licenses/by-nc/4.0/>), which permits non-commercial re-use, distribution, and reproduction in any medium, provided the original work is properly cited.

For commercial re-use, please contact journals.permissions@oup.com

Table 1: Laboratory tests on admission

Variable	Result	Normal range
TSH	1 mIU/l	0.4–4.0 mIU/l
PRL	27 ng/ml After cabergoline: 2 ng/ml	Non-pregnant: 2–29 ng/ml Pregnant: 10–209 ng/ml
E2 (estradiol)	64 pg/ml	15–350 pg/ml
FSH	4 IU/l	4.5–21.5 IU/l

**Figure 1:** Hysteroscopy showing a polyp-like mass in the uterine cavity.**Figure 2:** Photomicrograph ($\times 20$; hematoxylin-eosin [H-E] stain) of Fibrotic Abortion Tissue (Old Gestational Product Death). No Hyperplasia; No hydatidiform mole; No choriocarcinoma. Arrows pointing to fibrotic gestational villi (chronic villi).

hysterosalpingography (HSG) which showed no abnormality. We checked hormones levels in the blood and they were all within normal range (Table 1). We did a transvaginal ultrasound (TVUS) for the uterus and found no abnormality. Eventually, we did a hysteroscopy and found a 2.5×1.5 cm polyp-like mass in the fundus of the uterus (Fig. 1). The mass was excised and sent to pathology which revealed an endometrial stroma showing severe decidualization with a lot of gestational villi showing fibrosis and hyaline degeneration, features of old gestational product death, with no glands crowding or cellular atypia (Fig. 2). The duration in which these tissues were formed and then underwent fibrosis and hyaline degeneration was estimated to be a few years depending on the existing dystrophic calcification in it. The patient's partner underwent semen analysis, concerning number, shape of the sperm and its motility and the tests were normal. Afterwards, the patient underwent IVF with no success in conceiving.

DISCUSSION

Increased endogenous oestrogen and exogenous oestrogen administration, like tamoxifen, are risk factors for the formation of EP. EP can be single or multiple, sessile or pedunculated and measured in millimetres to centimetres. 95% of EP are benign. The risk of developing malignancy appears to be associated with the following: menopause, big size (>1.5 cm) and abnormal bleeding [3, 4].

Some EP are identified during the evaluation of abnormal bleeding, but many polyps are asymptomatic and only discovered during infertility evaluation [3].

Although there is no uniform approach in assessing RPL, TVUS is considered the first-line imaging test to investigate any

abnormality in the reproductive organs due to its low cost and convenience. Its sensitivity in detecting EP is 83.3% [5].

HSG is low-invasive radiography that uses a transcervical injection of iodinated contrast with concurrent fluoroscopy to reveal any occlusion in any part of the female reproductive cavities. However, HSG is less sensitive for the diagnosis of intrauterine pathology which in the case of EP has approximately a sensitivity of 50% compared with sonohysterography with a sensitivity up to 90% [6].

Hysteroscopy remains the gold standard for evaluation of the uterine cavity. On hysteroscopy, EP are found in up to 25% of women with unexplained infertility [3, 5].

Clinical suspicion of EP occurs during hysteroscopy, but the confirmation requires microscopic examination. Many pathological findings distinguish EP from the normal endometrium. In EP, the stroma is dense fibrous tissue; endometrial glands have parallel arrangement long axis to the surface epithelium; glands are often dilated, spaced closely together and have unusual shapes; and stromal blood vessels are thick-walled. Most EP have immature endometrium, which does not respond to hormones. Cystic hyperplasia is the dominant appearance of these polyps. They do not undergo the decidual changes and menstrual shedding. Less EP may be composed of functional endometrium, which changes histologically during the menstrual cycle [4]. In the case we present, the polyp did not contain glands crowding but endometrial stroma only, with a lot of fibrotic gestational villi.

EP have been associated with an increased probability of abnormal endometrial molecular expressions thought to impair implantation and early embryo development. Thus, EP have an adverse effect on endometrial receptivity. Polyp resection, polypectomy, is generally recommended for infertile women

prior to fertility treatments as hysteroscopy with polypectomy enhances chances for conception [7].

IVF technology is a promising solution for those who cannot conceive naturally. Many female factors play a role in determining whether the procedure will accomplish a successful gestation or not. Taking this fact into consideration, IVF has a probability to fail due to an impairment in one of those factors [8].

In our case, aside from the gestational product polyp, we could not identify the underlying cause of infertility, leaving it in the 50% of RPL cases with an unidentified cause [1].

A condition called missed abortion is when ultrasound (<14WG) shows no growth of intrauterine sac/embryo and/or loss of fetal heart activity of a confirmed pregnancy. This is close to what we present here, but missed abortion differs in causing amenorrhea [9], whereas in this case, the patient menstrual cycle was regular and normal in the presence of the polyp.

Another similar condition is retained products of conception which is described in the medical literature as a common problem after vaginal or caesarean delivery causing prolonged postpartum haemorrhage, fever and abdominal pain [10]. In our case, the conception products were not retained after a miscarriage or delivery, and also, they did not cause any symptoms indicating gestation after conceiving nor any symptoms indicating the death of the gestational products.

The asymptomatic endometrial polyp filled with fibrotic gestational villi without a prior miscarriage is an unprecedented case in the medical literature that may be added to the list of other findings that could present on infertility investigation. Therefore, take it into consideration while investigating for infertility-related EP. Also, emphasize the importance of pathological examination in infertility investigation which enables us, besides the clinical history, to distinguish the case from other findings that might present in an EP which can cause gestational impairment and differ in the treatment method.

ACKNOWLEDGEMENTS

The authors are grateful for Dr. Jamil Abrash, Fertility Medical centre, Hama Medical Centre, Hama, Syria, who provided us with the patient's history, and Yaseen Dhmesh, Faculty of Medicine, University of Hama, Hama, Syria, for his valuable support.

FUNDING

There is no funding.

ETHICAL APPROVAL

No approval was required.

PATIENT CONSENT

Written informed consent was obtained.

CONFLICT OF INTEREST STATEMENT

None declared.

REFERENCES

- Goncalves DR, Braga A, Braga J, Marinho A. Recurrent pregnancy loss and vitamin D: a review of the literature. *Am J Reprod Immunol* 2018;**80**:e13022. doi: [10.1111/aji.13022](https://doi.org/10.1111/aji.13022).
- ACOG practice bulletin. Management of recurrent pregnancy loss. Number 24, February 2001. (Replaces technical bulletin number 212, September 1995). American College of Obstetricians and Gynecologists. *Int J Gynaecol Obstet* 2002;**78**:179–90. doi: [10.1016/s0020-7292\(02\)00197-2](https://doi.org/10.1016/s0020-7292(02)00197-2).
- Rackow BW, Jorgensen E, Taylor HS. Endometrial polyps affect uterine receptivity. *Fertil Steril* 2011;**95**:2690–2. doi: [10.1016/j.fertnstert.2010.12.034](https://doi.org/10.1016/j.fertnstert.2010.12.034).
- Nijkang NP, Anderson L, Markham R, Manconi F. Endometrial polyps: pathogenesis, sequelae and treatment. *SAGE Open Medicine* 2019;**7**: 2050312119848247:1–12. doi: [10.1177/2050312119848247](https://doi.org/10.1177/2050312119848247).
- Fadl SA, Sabry AS, Hippe DS, Al-Obaidli A, Yousef RR, Dubinsky TJ. Diagnosing polyps on transvaginal sonography: is sonohysterography always necessary? *Ultrasound Q* 2018;**34**:272–7. doi: [10.1097/RUQ.0000000000000384](https://doi.org/10.1097/RUQ.0000000000000384).
- Dishuck CF, Perchik JD, Porter KK, Gunn DD. Advanced imaging in female infertility. *Curr Urol Rep* 2019;**20**:77. doi: [10.1007/s11934-019-0942-0](https://doi.org/10.1007/s11934-019-0942-0).
- Munro MG. Uterine polyps, adenomyosis, leiomyomas, and endometrial receptivity. *Fertil Steril* 2019;**111**:629–40. doi: [10.1016/j.fertnstert.2019.02.008](https://doi.org/10.1016/j.fertnstert.2019.02.008).
- Liao S, Xiong J, Tu H, Hu C, Pan W, Geng Y et al. Prediction of in vitro fertilization outcome at different antral follicle count thresholds combined with female age, female cause of infertility, and ovarian response in a prospective cohort of 8269 women. *Medicine* 2019;**98**:e17470. doi: [10.1097/md.00000000000017470](https://doi.org/10.1097/md.00000000000017470).
- Delabaere A, Huchon C, Lavoue V, Lejeune V, Iraola E, Nedelec S et al. Definition of pregnancy losses: standardization of terminology from the French National College of Obstetricians and Gynecologists (CNGOF). *J Gynecol Obstet Biol Reprod (Paris)* 2014;**43**:756–63. doi: [10.1016/j.jgyn.2014.09.010](https://doi.org/10.1016/j.jgyn.2014.09.010).
- Levinsohn-Tavor O, Feldman N, Svirsky R, Smorgick N, Nir-Yoffe A, Maymon R. Ultrasound criteria for managing postpartum patients with suspicion of retention of conception products. *Acta Radiol* 2020;**61**:276–81. doi: [10.1177/0284185119855185](https://doi.org/10.1177/0284185119855185).